



Spontaneous Extraperitoneal Bladder Wall Rupture Due to Emphysematous Cystitis: A Case Report and Literature Review

Mahdi Ramezani-Binabaj* and Seyed Reza Yahyazadeh

Department of Urology, Shariati Hospital, Faculty of Medicine, Tehran University of Medical Sciences, Tehran, Iran

* Corresponding author

Mahdi Ramezani-Binabaj, MD

Department of Urology, Shariati Hospital, Faculty of Medicine, Tehran University of Medical Sciences, Tehran, Iran

Tel: +98 21 8490 2469

Fax: +98 21 8863 3039

Email: ramezanimahdi70@gmail.com

Received: 15 Dec 2023

Accepted: 20 May 2024

Citation to this article

Ramezani-Binabaj M, Yahyazadeh SR. Spontaneous Extraperitoneal Bladder Wall Rupture Due to Emphysematous Cystitis: A Case Report and Literature Review. *J Iran Med Council*. 2025;8(2): 402-6.

Abstract

Emphysematous cystitis is a rare condition that can have fatal complications if left untreated. A timely diagnosis and proper treatment are crucial to achieving appropriate outcomes. Patients with this condition should be evaluated, and if necessary, conservative treatment or surgery should be provided. This case report describes a 73-year-old male patient with emphysematous cystitis who underwent conservative treatment for bladder rupture and reviews the existing literature on this topic. The gold standard for diagnosis of EC is a computerized tomographic scan. This condition should be evaluated, and if necessary, conservative treatment or surgery should be provided.

Keywords: Abdominal injuries, Aged, Conservative treatment, Cystitis, Humans, Male, Tomography, Urinary bladder, X-Ray computed

Introduction

Emphysematous Cystitis (EC) is an uncommon condition that mostly occurs in elderly female patients with diabetic cystopathy, immunodeficiency, bladder outlet obstruction, neurogenic bladder, recurrent urinary tract infections, or transplanted organs (1). The gold standard for diagnosing this condition is the Computerized Tomographic (CT) scan (2). It is diagnosed based on the presence of gas in the bladder wall and lumen. Spontaneous rupture of the bladder wall can occur rarely as a complication of EC. If it is not diagnosed and treated promptly, it can lead to peritonitis, sepsis, and eventually death (1). This condition is usually managed with antibiotic therapy or surgery (3). However, recent reports and international guidelines suggest that conservative treatment could be an option in extraperitoneal ruptures (4,5). Since there have been only scant case reports regarding bladder rupture in EC patients, management and treatment of this condition is remains underexplored with limited guidance. In this case report, a 73-year-old male patient with bladder rupture secondary to EC is presented and different treatment options based on a literature review and experience are discussed. Written informed consent was obtained from the patient for publication of this report.

Case Presentation

A 73-year-old male patient presented to the emergency room complaining of hematuria for one day. Other significant symptoms reported by the patient included vague pain in the lower abdomen and severe dysuria,

urgency, and frequency. Additionally, he experienced obstructive lower urinary tract symptoms such as intermittency and post-voiding dribbling. The patient had a medical history of Diabetes Mellitus (DM), Benign Prostate Enlargement (BPE), and hypertension. Furthermore, he had been hospitalized for 36 days due to COVID-19 and had been discharged four days earlier. To manage his COVID-19, the patient had been prescribed 25 mg of prednisolone daily, which was gradually tapered. Additionally, he took aspirin 80 mg daily to manage his underlying medical condition.

In the examinations, the patient was afebrile and had no symptoms of shock. At the time of admission to the hospital, he had a blood pressure of 110/90 mmHg, a pulse rate of 92/min, a respiratory rate of 16/min, and a temperature of 37.4°C. Aside from that, the patient had no costovertebral tenderness, lower abdomen tenderness, rebound tenderness, or guarding. Upon arrival, the laboratory data revealed leukocytosis (white blood cells: 13,700/mm³) and elevated C-reactive protein (CRP: 140 mg/L). Other laboratory results including hemoglobin, platelets, blood urea nitrogen, creatinine, and lactate were unremarkable. Bacteriuria, pyuria, and Hematuria were detected on urinalysis. The abdominopelvic CT scan revealed diffusely increased wall thickness and disruption of the bladder with air bubbles within the bladder wall and the para-vesicle spaces, indicating extraperitoneal dehiscence of the bladder wall (Figure 1).

In light of the patient's condition and the CT scan results, after taking the urine cultures, ceftriaxone 1 g

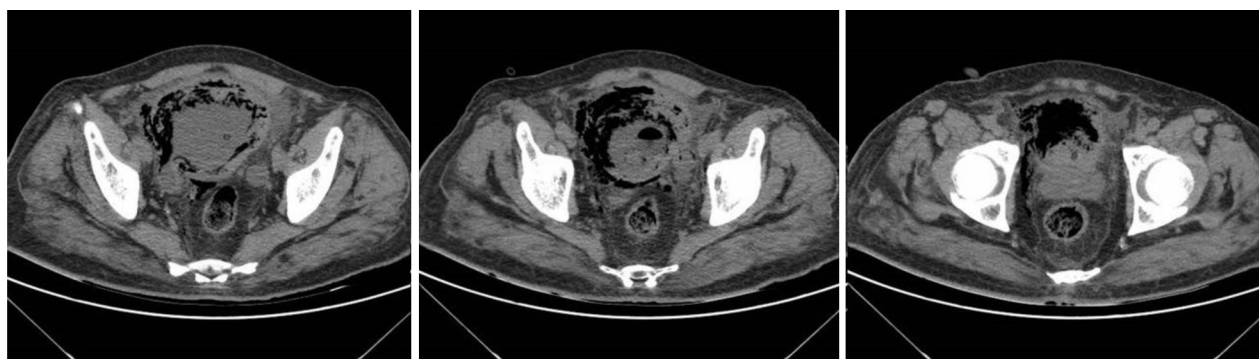

Figure 1. The Computed Tomography (CT) scan of the abdomen and pelvis revealed diffusely increased wall thickness with air bubbles within the bladder wall and disruption of the bladder wall with air bubbles within the para-vesicle spaces.

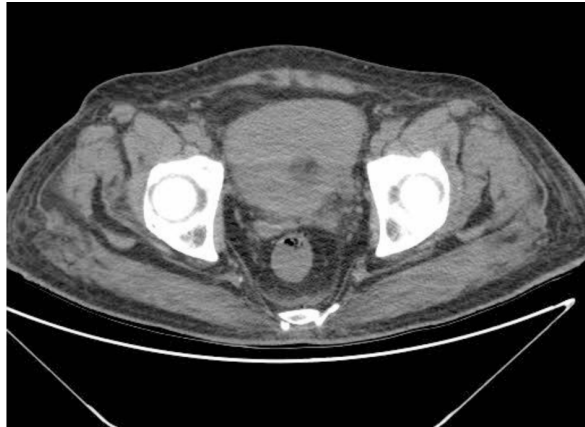


Figure 2. CT scan on the 10th day of the treatment revealed cure of bladder wall.

IV q 12 hr was started, and a catheter was placed for urine drainage. The urine culture revealed *Escherichia coli* as the cause of the infection and it was sensitive to the third-generation cephalosporin. Seventy-two hours after initiating the antibiotic therapy, the symptoms were improved. A repeat CT scan on day 10 of the treatment (Figure 2) showed that the bladder wall was cured, and the patient was discharged. The patient's blood sugar was controlled during the follow-up, and an alpha-blocker was started to treat his BPE. The catheter was removed one week after discharge. The patient was followed for six months later, and he had no lower urinary tract symptoms or hematuria during this period.

Discussion

Emphysematous cystitis is a rare condition that can be fatal if not diagnosed and treated appropriately in a timely manner (6). Bladder rupture due to EC is an uncommon complication of this disease. In this report, we describe a case of EC with bladder rupture that was managed by urinary drainage and proper antibiotic therapy. A review of the English literature was also conducted using the search terms “emphysematous cystitis” and “bladder rupture” in the title and abstract of articles in PubMed and Google scholar until June 14, 2022. Intra-peritoneal bladder ruptures were excluded. A total of 5 case reports were found and they are summarized in table 1 (1,4,5,7,8). EC has several known risk factors, including poorly controlled diabetes, bladder outlet obstruction, recurrent urinary tract infections, immunosuppression,

female gender, transplant recipients, and conditions causing urinary stasis such as the neurogenic bladder (9). Among the reported cases of bladder rupture due to EC, DM was the most prevalent predisposing factor (43.75%). The aforementioned case had uncontrolled diabetes, BPE-related retention, and prednisolone-related immunosuppression, which predisposed him to the EC. A distinguishing characteristic of this patient was his male gender. Meanwhile, most of the previously reported cases were female (75%).

The presentation and prognosis of emphysematous cystitis were very diverse (10). Based on the available literature, the most common symptoms were abdominal pain with the highest prevalence, followed by pneumaturia, dysuria, frequency, and urgency (3). Although pneumaturia is one of the first specific symptoms of this disease, it has not been reported in any of the patients who had a ruptured bladder (Table 1), including ours. The aforementioned patient had no pneumaturia and was instead suffering from macroscopic hematuria, which was also present in three of the reported cases (1,11,12). This review showed that abdominal pain (56.25%) and fever (50%) are the most prevalent symptom among these patients.

Escherichia coli (*E. coli*) (61.58%) and *Klebsiella pneumoniae* (23.07%) are the main culprits reported in the previous case reports. There are also reports of patients with positive culture of *Enterococcus Faecium*, *Acinetobacter baumannii*, *Enterobacter cloacae*, *Enterococcus faecalis*, *Enterococcus gallinarum* and *Candida Albicans* (8,11,13). The urine culture of the aforementioned patient was also positive for *E-Coli*. There is no general agreement available for the treatment of bladder rupture due to emphysematous cystitis. Intraperitoneal ruptures are usually accompanied by acute abdomen or sepsis, requiring surgical repair (5). Some previous studies have recommended managing uncomplicated extraperitoneal ruptures conservatively, similar to other cases of EC, with broad spectrum antibiotics, glycemic control, and correction of underlying comorbid disorders (7,14). Our patient was also treated conservatively without any surgical intervention due to the absence of critical complications from bladder rupture. Although the prognosis is exceptionally diverse, experts believe that the key factors in

Table 1. Extra-peritoneal bladder rupture due to emphysematous cystitis cases reported in English literatures have been published on this disease until June 14, 2022

Year/ Author	Age	Gender	Predisposing risk factor	Clinical presentation	Urine culture results	Radiologic finding	Management/final outcome
2009/Hu SY ⁷	82	Female	Pervious history of lung cancer with surgery and radiotherapy	Abdominal pain with tenderness	<i>E. coli</i>	Extra peritoneal perforation	Antibiotic therapy- did not consent to the surgery- the patient died
2021/ Okello C ¹	84	Male	Peritoneal dialysis	Hematuria, Voiding symptoms, Fever, Hypotension and Mild suprapubic tenderness	<i>E. coli</i>	Small perforation at the bladder dome	Antibiotic therapy and conservative management-the patient survived
2016/ Roels P ⁵	74	Female	-	Suprapubic pain and progressive deterioration of general condition	<i>E. coli</i>	Extraperitoneal bladder perforation	Antibiotic therapy and conservative management-the patient survived
2012/Qin Y ⁴	86	Female	Post-operative	Vomiting, Constipation and Lethargy	<i>Klebsiella pneumoniae</i>	Extraperitoneal bladder perforation	Antibiotic therapy and conservative management-the patient survived
2012/ Tsubouchi K ⁸	77	Female	DM-Cerebral infarction	Fever	<i>E. coli</i> , <i>Enterobacter cloacae</i> , <i>Enterococcus faecalis</i> , <i>Enterococcus gallinarum</i>	Extraperitoneal bladder perforation	Antibiotic therapy and surgery-the patient survived

determining the prognosis in these patients are timely initiation of conventional therapy and the patient's condition at presentation. Despite the logical conclusion that the prognosis for patients with kidney and ureter involvement requiring surgery would be worse, several guidelines recommend conservative treatment in patients with a small, uncomplicated intraperitoneal rupture of the bladder wall (1,15).

Conclusion

One of the important manifestations of Emphysematous cystitis is bladder rupture, which is a life-threatening condition. It is imperative that these patients be evaluated early and appropriately, and that they receive either conservative treatment or surgery. Patients who have stable conditions and respond adequately to medical treatment may not require

surgery.

Consent for publication

Written informed consent was obtained from the patient for publishing this case report and any accompanying images. A copy of the written consent is available for review by the Editor-in-Chief of this journal.

Funding/Support

This research did not receive any specific grant from funding agencies in the public, commercial, or not-for-profit sectors.

Conflict of Interest

The authors declare no conflict of interest.

References

1. Okello C, Raj R. A complex case of emphysematous cystitis in a peritoneal dialysis patient. *Case Rep Nephrol* 2021 Jul 7;2021:8343022.
2. Rajaian S, Murugavaithianathan P, Krishnamurthy K, Murugasen L. Emphysematous cystitis: diagnosed only if suspected. *BMJ Case Rep* 2019 Jul 17;12(7):e230715.
3. Wojack PR, Goldman IA. Emphysematous cystitis with extraperitoneal gas: new insights into pathogenesis via novel CT findings. *Clin Imaging*. 2020 Sep;65:1-4.
4. Qin Y, Tulsidas H, Jaufeerally F, Tan RK. Emphysematous cystitis complicated by urinary bladder perforation: a case report. *Proc Singap Healthc* 2012 Jun;21(2):140-3.
5. Roels P, Decaestecker K, De Visschere P. Spontaneous bladder wall rupture due to emphysematous cystitis. *J Belg Soc Radiol* 2016 Oct 18;100(1):83.
6. Zhang WJ, Zhu ZM, Luo HL. Severe emphysematous cystitis complicated with perforation, bilateral renal cortical atrophy and sepsis: a case report. *J Int Med Res* 2020 Jul;48(7):300060520937920.
7. Hu SY, Tsan YT. Emphysematous cystitis with perforation in a non-diabetic patient. *Postgrad Med J* 2009 Jun;85(1004):292.
8. Tsubouchi K, Irie S, Mikuriya M, Yoshida K, Tanaka M. [Rupture of the urinary bladder due to emphysematous cystitis: a case report]. *Nihon Hinyokika Gakkai Zasshi*. 2012 Jul;103(4):627-30. Japanese.
9. Ranjan SK, Navriya SC, Kumar S, Mittal A, Bhirud DP. Emphysematous cystitis: a case report and literature review of 113 cases. *Urol Ann* 2021 Jul-Sep;13(3):312-15.
10. Chong SJ, Lim KB, Tan YM, Chow RK, Yip SK. Atypical presentations of emphysematous cystitis. *Surgeon* 2005 Apr;3(2):109-12.
11. Kim KS, Moon SY, Yoon JU, Lee SS, Cho JS, Chung DR. Emphysematous cystitis with bladder rupture by *Candida albicans*. *Infect Chemother* 2005:107-10.
12. Hudnall MT, Jordan BJ, Horowitz J, Kielb S. A case of emphysematous cystitis and bladder rupture. *Urol Case Rep* 2019 Mar 6;24:100860.
13. Viswanathan S, Rajan RP, Iqbal N, Subramani J, Muthu V. Enterococcus faecium related emphysematous cystitis and bladder rupture. *Australas Med J* 2012;5(11):581-4.
14. Simon LV, Sajjad H, Lopez RA, Burns B. Bladder Rupture. *StatPearls Publishing*;2024 Jan.
15. Oh SB, Ahn JH. Successful conservative management of a spontaneous intraperitoneal rupture of bladder diverticulum in a critical patient: a case report. *ACARE-compliant article. Medicine (Baltimore)* 2020 Feb;99(7):e19262.